

# Protocol for the Examination of Specimens from Patients with Carcinoma of the Stomach

**Protocol applies to all invasive carcinomas of the stomach. Tumors of the esophagogastric junction and well-differentiated neuroendocrine tumors (carcinoid tumors) are not included.**

---

**Based on AJCC/UICC TNM, 7th edition**

Protocol web posting date: October 2009

## **Procedures**

- Endoscopic Resection
- Gastrectomy (Partial or Complete)

## **Authors**

Kay Washington, MD, PhD, FCAP\*

Department of Pathology, Vanderbilt University Medical Center, Nashville, TN

Jordan Berlin, MD

Department of Medicine, Vanderbilt University Medical Center, Nashville, TN

Philip Branton, MD, FCAP

Department of Pathology, Inova Fairfax Hospital, Falls Church, VA

Lawrence J. Burgart, MD, FCAP

Allina Laboratories, Abbott Northwestern Hospital, Minneapolis, MN

David K. Carter, MD, FCAP

Department of Pathology, St. Mary's/Duluth Clinic Health System, Duluth, MN

Patrick Fitzgibbons, MD, FCAP

Department of Pathology, St. Jude Medical Center, Fullerton, CA

Wendy L. Frankel, MD, FCAP

Department of Pathology, Ohio State University Medical Center, Columbus, OH

John Jessup, MD

Division of Cancer Treatment and Diagnosis, National Cancer Institute, Bethesda, MD

Sanjay Kakar, MD, FCAP

Department of Pathology, University of California San Francisco and the Veterans Affairs Medical Center, San Francisco, CA

Bruce Minsky, MD

Department of Radiation Oncology, University of Chicago, Chicago, IL

Raouf Nakhleh, MD, FCAP

Department of Pathology, Mayo Clinic, Jacksonville, FL

Carolyn C. Compton, MD, PhD, FCAP†

Office of Biorepositories and Biospecimen Research, National Cancer Institute, Bethesda, MD

For the Members of the Cancer Committee, College of American Pathologists

\*denotes primary author. † denotes senior author. All other contributing authors are listed alphabetically.

**Previous contributor:** Leslie H. Sobin, MD

© 2009 College of American Pathologists (CAP). All rights reserved.

The College does not permit reproduction of any substantial portion of these protocols without its written authorization. The College hereby authorizes use of these protocols by physicians and other health care providers in reporting on surgical specimens, in teaching, and in carrying out medical research for nonprofit purposes. This authorization does not extend to reproduction or other use of any substantial portion of these protocols for commercial purposes without the written consent of the College.

The CAP also authorizes physicians and other health care practitioners to make modified versions of the Protocols solely for their individual use in reporting on surgical specimens for individual patients, teaching, and carrying out medical research for non-profit purposes.

The CAP further authorizes the following uses by physicians and other health care practitioners, in reporting on surgical specimens for individual patients, in teaching, and in carrying out medical research for non-profit purposes: (1) **Dictation** from the original or modified protocols for the purposes of creating a text-based patient record on paper, or in a word processing document; (2) **Copying** from the original or modified protocols into a text-based patient record on paper, or in a word processing document; (3) The use of a **computerized system** for items (1) and (2), provided that the Protocol data is stored intact as a single text-based document, and is not stored as multiple discrete data fields.

Other than uses (1), (2), and (3) above, the CAP does not authorize any use of the Protocols in electronic medical records systems, pathology informatics systems, cancer registry computer systems, computerized databases, mappings between coding works, or any computerized system without a written license from CAP. Applications for such a license should be addressed to the SNOMED Terminology Solutions division of the CAP.

Any public dissemination of the original or modified Protocols is prohibited without a written license from the CAP.

The College of American Pathologists offers these protocols to assist pathologists in providing clinically useful and relevant information when reporting results of surgical specimen examinations of surgical specimens. The College regards the reporting elements in the "Surgical Pathology Cancer Case Summary (Checklist)" portion of the protocols as essential elements of the pathology report. However, the manner in which these elements are reported is at the discretion of each specific pathologist, taking into account clinician preferences, institutional policies, and individual practice.

The College developed these protocols as an educational tool to assist pathologists in the useful reporting of relevant information. It did not issue the protocols for use in litigation, reimbursement, or other contexts. Nevertheless, the College recognizes that the protocols might be used by hospitals, attorneys, payers, and others. Indeed, effective January 1, 2004, the Commission on Cancer of the American College of Surgeons mandated the use of the checklist elements of the protocols as part of its Cancer Program Standards for Approved Cancer Programs. Therefore, it becomes even more important for pathologists to familiarize themselves with these documents. At the same time, the College cautions that use of the protocols other than for their intended educational purpose may involve additional considerations that are beyond the scope of this document.

The inclusion of a product name or service in a CAP publication should not be construed as an endorsement of such product or service, nor is failure to include the name of a product of service to be construed as disapproval.

## Surgical Pathology Cancer Case Summary (Checklist)

Protocol web posting date: October 2009

### **STOMACH: Local Resection, Gastrectomy (Note A)**

**Select a single response unless otherwise indicated.**

#### **Specimen (select all that apply)**

- Stomach  
 Portion of stomach  
      Gastric body  
      Gastric antrum  
 Distal esophagus  
 Proximal duodenum  
 Not specified

#### **Procedure**

- Endoscopic resection  
 Partial gastrectomy, proximal  
 Partial gastrectomy, distal  
 Partial gastrectomy, other (specify): \_\_\_\_\_  
 Total gastrectomy  
 Other (specify): \_\_\_\_\_  
 Not specified

#### **Tumor Site (select all that apply) (Note B)**

- Fundus  
     \*  Anterior wall  
     \*  Posterior wall  
 Body  
     \*  Anterior wall  
     \*  Posterior wall  
     \*  Lesser curvature  
     \*  Greater curvature  
 Antrum  
     \*  Anterior wall  
     \*  Posterior wall  
     \*  Lesser curvature  
     \*  Greater curvature  
 Other (specify): \_\_\_\_\_  
 Not specified

#### **Tumor Size**

- Greatest dimension: \_\_\_\_ cm  
 \*Additional dimensions: \_\_\_\_ x \_\_\_\_ cm  
 Cannot be determined (see Comment)

\* Data elements with asterisks are not required. However, these elements may be clinically important but are not yet validated or regularly used in patient management.

**Histologic Type (Note C)**

- Adenocarcinoma, intestinal type
- Adenocarcinoma, diffuse type
- Papillary adenocarcinoma
- Tubular adenocarcinoma
- Mucinous adenocarcinoma (greater than 50% mucinous)
- Signet-ring cell carcinoma (greater than 50% signet-ring cells)
- Other (specify): \_\_\_\_\_
- Carcinoma, not otherwise specified

**Histologic Grade (Note D)**

- Not applicable
- GX: Cannot be assessed
- G1: Well differentiated
- G2: Moderately differentiated
- G3: Poorly differentiated
- G4: Undifferentiated
- Other (specify): \_\_\_\_\_

**Microscopic Extent of Tumor**

- High-grade dysplasia/carcinoma in situ
- Tumor invades lamina propria
- Tumor invades muscularis mucosae
- Tumor invades submucosa
- Tumor invades muscularis propria
- Tumor invades subserosal connective tissue
- Tumor penetrates serosa (visceral peritoneum)
- Tumor directly invades adjacent structures (specify): \_\_\_\_\_
- Tumor penetrates to the surface of the visceral peritoneum (serosa) AND directly invades adjacent structures (specify: \_\_\_\_\_)

**Margins (select all that apply) (Note E)**Proximal Margin

- Cannot be assessed
- Uninvolved by invasive carcinoma
- Involved by invasive carcinoma
- Carcinoma in situ/adenoma not identified at proximal margin
- Carcinoma in situ/adenoma present at proximal margin

Distal Margin

- Cannot be assessed
- Uninvolved by invasive carcinoma
- Involved by invasive carcinoma
- Carcinoma in situ/adenoma not identified at distal margin
- Carcinoma in situ/adenoma present at distal margin

\* Data elements with asterisks are not required. However, these elements may be clinically important but are not yet validated or regularly used in patient management.

Omental (Radial) Margins

- Cannot be assessed  
 Uninvolved by invasive carcinoma  
 Lesser omental margin involved by invasive carcinoma  
 Greater omental margin involved by invasive carcinoma

Deep Margin (applies to endoscopic resections)

- Cannot be assessed  
 Uninvolved by invasive carcinoma  
 Involved by invasive carcinoma  
 Not applicable

If all margins uninvolved by invasive carcinoma:

Distance of invasive carcinoma from closest margin: \_\_\_ mm

Specify margin: \_\_\_\_\_

**Treatment Effect (applicable to carcinomas treated with neoadjuvant therapy)****(Note F)**

- No prior treatment  
 Present
  - \*  No residual tumor (complete response, grade 0)
  - \*  Marked response (grade 1, minimal residual cancer)
  - \*  Moderate response (grade 2) No definite response identified (grade 3, poor or no response)  
 Not known

**Lymph-Vascular Invasion (Note G)**

- Not identified  
 Present  
 Indeterminate

**\*Perineural Invasion (Note H)**

- Not identified  
 Present  
 Indeterminate

**Pathologic Staging (pTNM) (Note I)**

TNM Descriptors (required only if applicable) (select all that apply)

- m (multiple primary tumors)  
 r (recurrent)  
 y (post-treatment)

\* Data elements with asterisks are not required. However, these elements may be clinically important but are not yet validated or regularly used in patient management.

Primary Tumor (pT)

- pTX: Cannot be assessed  
 pT0: No evidence of primary tumor  
 pTis: Carcinoma in situ  
 pT1: Tumor invades lamina propria, muscularis mucosae, or submucosa  
 pT1a: Tumor invades lamina propria or muscularis mucosae  
 pT1b: Tumor invades submucosa  
 pT2: Tumor invades muscularis propria  
 pT3: Tumor invades subserosal connective tissue, without involvement of visceral peritoneum or adjacent structures  
 pT4: Tumor involves serosa (visceral peritoneum) or adjacent structures  
 pT4a: Tumor invades serosa (visceral peritoneum)  
 pT4b: Tumor invades adjacent structures

Regional Lymph Nodes (pN) (Note J)

- pNX: Cannot be assessed  
 pN0: No regional lymph node metastasis  
 pN1: Metastasis in 1 to 2 perigastric lymph nodes  
 pN2: Metastasis in 3 to 6 perigastric lymph nodes  
 pN3: Metastasis in 7 or more perigastric lymph nodes  
 pN3a: Metastasis in 7 to 15 perigastric lymph nodes  
 pN3b: Metastasis in 16 or more perigastric lymph nodes  
 Specify: Number examined: \_\_\_\_  
           Number involved: \_\_\_\_

Distant Metastasis (pM)

- Not applicable  
 pM1: Distant metastasis  
           \*Specify site(s), if known: \_\_\_\_\_

**\*Additional Pathologic Findings (select all that apply) (Note K)**

- \*  None identified  
 \*  Intestinal metaplasia  
 \*  Dysplasia  
 \*  Gastritis  
     \*  *Helicobacter pylori*-type gastritis  
     \*  Other gastritis (specify): \_\_\_\_\_  
 \*  Polyp(s) (type[s]): \_\_\_\_\_  
 \*  Other (specify): \_\_\_\_\_

**\*Ancillary Studies**

- \*Specify: \_\_\_\_\_  
 \*  Not performed

**\*Clinical History (select all that apply) (Note L)**

- \*  Previous gastric surgery (specify): \_\_\_\_\_  
 \*  Other (specify): \_\_\_\_\_  
 \*  Not known

**\*Comment(s)**

\* Data elements with asterisks are not required. However, these elements may be clinically important but are not yet validated or regularly used in patient management.

## Explanatory Notes

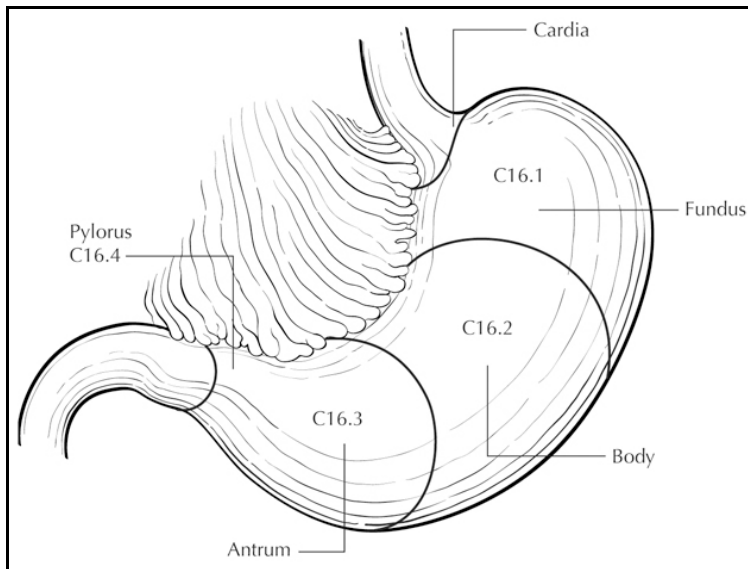
### A. Application

This protocol applies to all carcinomas that arise in the stomach and do not involve the esophagogastric junction (EGJ). Tumors that arise in the proximal stomach within 5 cm of the EGJ and cross the EGJ are not included. Lymphomas, low-grade neuroendocrine tumors (carcinoid tumors), and sarcomas are also not included (separate TNM staging systems<sup>1</sup> and College of American Pathologists (CAP) protocols apply).

### B. Tumor Site

Tumor location should be described in relation to the following landmarks (Figure 1):

- gastric region: cardia (including EGJ), fundus, corpus, antrum, pylorus
- greater curvature, lesser curvature
- anterior wall, posterior wall



**Figure 1.** Anatomical subsites of the stomach. From: Greene FL, Compton, CC, Fritz AG, et al, eds. *AJCC Cancer Staging Atlas*. New York: Springer; 2006. Copyright © American Joint Committee on Cancer. Used with permission.

Tumors involving the EGJ are classified for purposes of staging as esophageal carcinomas,<sup>1</sup> and the CAP protocol for the esophagus should be used for such tumors. The EGJ is defined as the junction of the tubular esophagus and the stomach irrespective of the type of epithelial lining of the esophagus. Although the nature of these tumors (gastric versus esophageal) has been controversial<sup>2,3</sup> (reviewed by Carneiro and Chaves<sup>4</sup>), recent data support their classification as esophageal carcinomas.<sup>1</sup> The World Health Organization (WHO) defines esophageal tumors as those located entirely above the EGJ and proximal gastric tumors as those located entirely below the EGJ.<sup>5</sup> Tumors crossing the EGJ are classified as EGJ tumors. An alternative system proposed by Siewart and colleagues divides adenocarcinomas involving the EGJ into three categories,<sup>6</sup> based upon location of the midpoint of the tumor:

Type I: adenocarcinoma of the distal esophagus, with or without infiltration of the EGJ from above

Type II: true carcinoma of the gastric cardia, arising from the cardiac epithelium or short segments with intestinal metaplasia at the EGJ

Type III: subcardial gastric carcinoma, which infiltrates the EGJ and distal esophagus from below

Application of the Siewart system is complicated by lack of consensus as to the definition and nature of the gastric cardia, with some investigators regarding it as a normal anatomic finding,<sup>7</sup> and others as a metaplastic response to injury from esophagogastric reflux,<sup>2</sup> reviewed by Carneiro and Chaves.<sup>44</sup>

Although some studies have shown no prognostic impact for tumor site,<sup>8</sup> others have shown a poorer outcome for proximal gastric cancers than for distal tumors.<sup>9</sup>

### C. Histologic Type

For consistency in reporting, the histologic classification proposed by the World Health Organization (WHO) is recommended.<sup>5</sup> However, this protocol does not preclude the use of other systems of classification or histologic types, such as the Laurén classification,<sup>10</sup> which may be used in addition to the WHO system.

With the exception of the rare small cell carcinoma of the stomach, which has an unfavorable prognosis, most multivariate analyses show no effect of tumor type, independent of stage, on prognosis.<sup>9</sup>

### WHO Classification of Carcinoma of the Stomach

Adenocarcinoma

    Intestinal type

    Diffuse type

Papillary adenocarcinoma

Tubular adenocarcinoma

Mucinous adenocarcinoma (greater than 50% mucinous)

Signet-ring cell carcinoma (greater than 50% signet-ring cells)

Adenosquamous carcinoma

Squamous cell carcinoma

Small cell carcinoma

Undifferentiated carcinoma

Other (specify)

The Laurén classification, namely intestinal or diffuse type, and/or the Ming classification, namely expanding or infiltrating type, may also be included; in general, significant correlation is seen between the various classification systems.<sup>11</sup>

The WHO classifies in situ carcinoma as intraepithelial neoplasia. The term “carcinoma, NOS (not otherwise specified)” is not part of the WHO classification.

**D. Histologic Grade**

For adenocarcinomas, a histologic grade that is based on the extent of glandular differentiation is suggested, as shown below.

Grade X	Cannot be assessed
Grade 1	Well differentiated (greater than 95% of tumor composed of glands)
Grade 2	Moderately differentiated (50% to 95% of tumor composed of glands)
Grade 3	Poorly differentiated (49% or less of tumor composed of glands)

Tubular adenocarcinomas are not typically graded but are low grade and would correspond to grade 1.

Signet-ring cell carcinomas are high grade and are classified as grade 3.

Small cell carcinomas and undifferentiated carcinomas are classified as grade 4.

For squamous cell carcinomas (rare), a suggested histologic grading system is shown below.

Grade X	Grade cannot be assessed
Grade 1	Well differentiated
Grade 2	Moderately differentiated
Grade 3	Poorly differentiated

Note: Undifferentiated tumors cannot be specifically categorized as adenocarcinoma or squamous cell carcinoma. Instead, they are classified as undifferentiated carcinoma by the WHO classification and are assigned grade 4 (see Note C).

Although grade has been shown to have little impact on survival for patients undergoing complete tumor resection,<sup>12</sup> it has a significant impact on margin-negative resectability, with higher-grade tumors less likely to be resectable.

**E. Margins**

For surgical resection specimens, margins include the proximal, distal, and radial margins. The radial margins represent the nonperitonealized soft tissue margins closest to the deepest penetration of tumor. In the stomach, the lesser omental (hepatoduodenal and hepatogastric ligaments) and greater omental resection margins are the only radial margins. For endoscopic resection specimens, margins include mucosal margins and the deep margin of resection. It may be helpful to mark the margin(s) closest to the tumor with ink. Margins marked by ink should be designated in the macroscopic description.

**F. Treatment Effect**

Response of tumor to previous chemotherapy or radiation therapy should be reported. Although grading systems for tumor response have not been established, in general, 3-category systems provide good interobserver reproducibility.<sup>13</sup> The following system is suggested:

**Tumor Regression Grade**

Description	Tumor Regression Grade
No viable cancer cells	0 (Complete response)
Single cells or small groups of cancer cells	1 (Moderate response)
Residual cancer outgrown by fibrosis	2 (Minimal response)
Minimal or no tumor kill; extensive residual cancer	3 (Poor response)

Sizable pools of acellular mucin may be present after chemoradiation but should not be interpreted as representing residual tumor.

This protocol does not preclude the use of other systems for assessment of tumor response, such as the schemes reported by Memorial Sloan-Kettering Cancer Center investigators and others.<sup>14,15</sup>

**G. Venous/Lymphatic Vessel Invasion**

Both venous<sup>16</sup> and lymphatic vessel<sup>9</sup> invasion have been shown to be adverse prognostic factors<sup>14</sup> and are predictive of lymph node metastases in early gastric cancers.<sup>17</sup> However, the microscopic presence of tumor in lymphatic vessels or veins does not qualify as local extension of tumor as defined by the T classification.<sup>1</sup>

**H. Perineural Invasion**

Perineural invasion has been shown to be an adverse prognostic factor<sup>14</sup> and has been associated with lymph node metastases in early gastric cancer in univariate but not multivariate analyses.<sup>17</sup>

**I. TNM and Anatomic Stage/Prognostic Groupings**

The TNM staging system for gastric carcinoma of the American Joint Committee on Cancer (AJCC) and the International Union Against Cancer (UICC) is recommended and shown below.<sup>1</sup>

According to AJCC/UICC convention, the designation “T” refers to a primary tumor that has not been previously treated. The symbol “p” refers to the pathologic classification of the TNM, as opposed to the clinical classification, and is based on gross and microscopic examination. pT entails a resection of the primary tumor or biopsy adequate to evaluate the highest pT category, pN entails removal of nodes adequate to validate lymph node metastasis, and pM implies microscopic examination of distant lesions. Clinical classification (cTNM) is usually carried out by the referring physician before treatment during initial evaluation of the patient or when pathologic classification is not possible.

Pathologic staging is usually performed after surgical resection of the primary tumor. Pathologic staging depends on pathologic documentation of the anatomic extent of disease, whether or not the primary tumor has been completely removed. If a biopsied tumor is not resected for any reason (eg, when technically infeasible) and if the highest T and N categories or the M1 category of the tumor can be confirmed microscopically, the

criteria for pathologic classification and staging have been satisfied without total removal of the primary cancer.

### TNM Descriptors

For identification of special cases of TNM or pTNM classifications, the “m” suffix and “y,” “r,” and “a” prefixes are used. Although they do not affect the stage grouping, they indicate cases needing separate analysis.

The “m” suffix indicates the presence of multiple primary tumors in a single site and is recorded in parentheses: pT(m)NM.

The “y” prefix indicates those cases in which classification is performed during or after initial multimodality therapy (ie, neoadjuvant chemotherapy, radiation therapy, or both chemotherapy and radiation therapy). The cTNM or pTNM category is identified by a “y” prefix. The ycTNM or ypTNM categorizes the extent of tumor actually present at the time of that examination. The “y” categorization is not an estimate of tumor before multimodality therapy (ie, before initiation of neoadjuvant therapy).

The “r” prefix indicates a recurrent tumor when staged after a documented disease-free interval and is identified by the “r” prefix: rTNM.

The “a” prefix designates the stage determined at autopsy: aTNM.

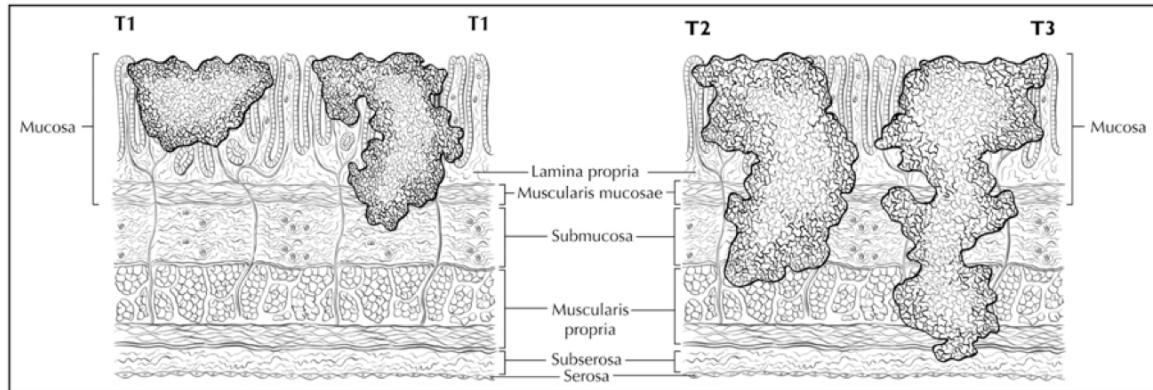
### Primary Tumor (T) (Figures 2-4)

TX	Primary tumor cannot be assessed
T0	No evidence of primary tumor
Tis	Carcinoma in situ: intraepithelial tumor without invasion of the lamina propria
T1	Tumor invades lamina propria, muscularis mucosae, or submucosa
T1a	Tumor invades lamina propria <sup>#</sup>
T1b	Tumor invades submucosa <sup>#</sup>
T2	Tumor invades muscularis propria <sup>##</sup>
T3	Tumor penetrates subserosal connective tissue without invasion of visceral peritoneum or adjacent structures
T4	Tumor invades serosa (visceral peritoneum) or adjacent structures
T4a	Tumor invades serosa (visceral peritoneum)
T4b	Tumor invades adjacent structures <sup>###</sup>

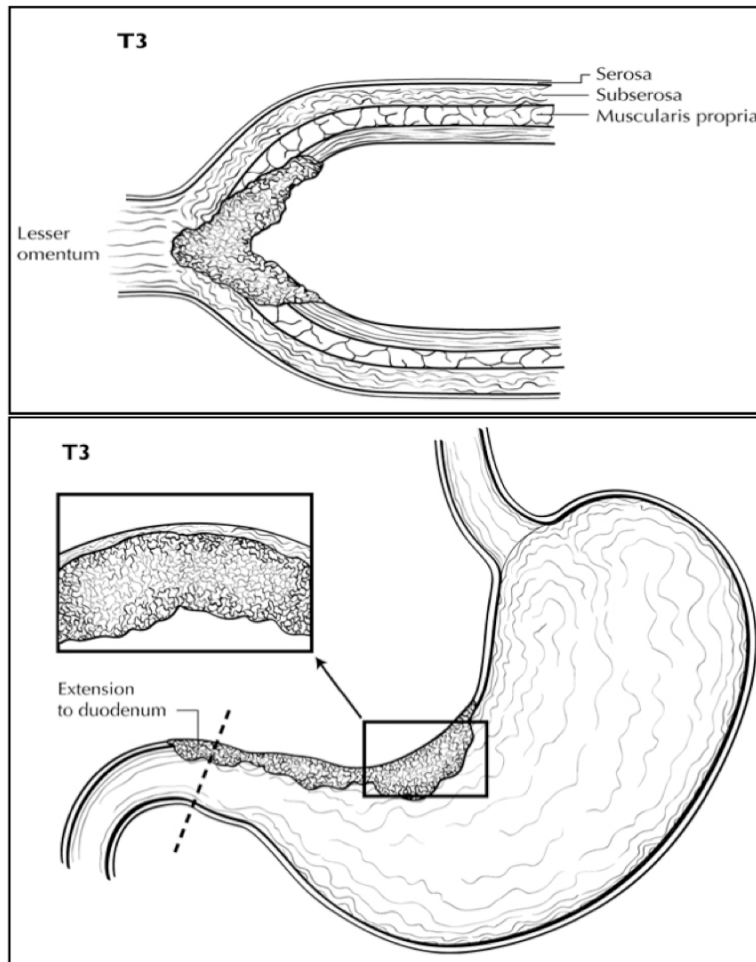
<sup>#</sup> The T1 category has been expanded on the basis of the observed difference in frequency of lymph node metastasis. In addition, the substratifications may be important as indicators for treatment by limited procedures.<sup>8</sup>

<sup>##</sup> A tumor may penetrate the muscularis propria with extension into the gastrocolic or gastrohepatic ligaments or into the greater or lesser omentum without perforation of the visceral peritoneum covering these structures. In this case, the tumor would be classified as T3. If there is perforation of the visceral peritoneum covering the gastric ligaments or omenta, the tumor is classified as T4.

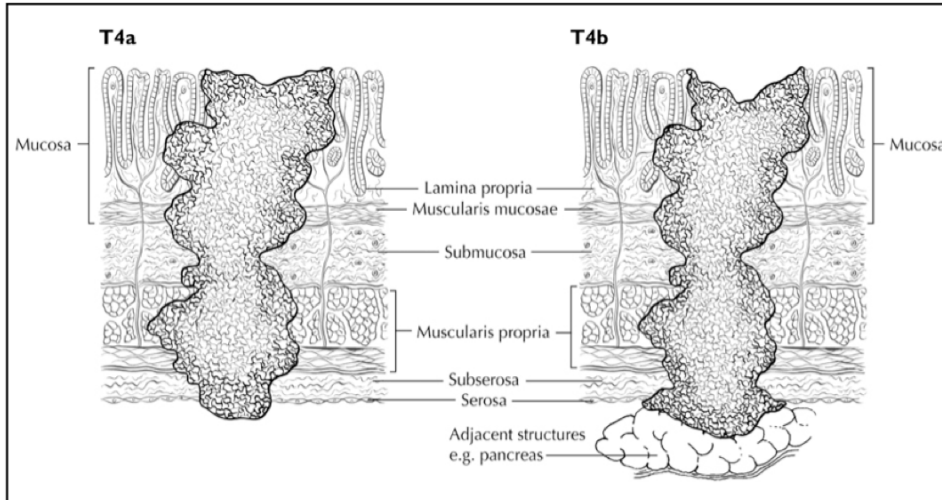
### The adjacent structures of the stomach are the spleen, transverse colon, liver, diaphragm, pancreas, abdominal wall, adrenal gland, kidney, small intestine, and retroperitoneum. Intramural extension into the duodenum or esophagus is classified by the depth of greatest invasion in any of these sites, including the stomach.



**Figure 2.** Definitions of T1, T2, and T3. Tumor invading the lamina propria is classified as T1a (left side or T1 illustration), whereas tumor invading the submucosa is classified as T1b (right side). T2 tumor invades the muscularis propria. T3 tumor invades the subserosal adipose tissue. Modified from: Greene FL, Compton, CC, Fritz AG, et al, eds. *AJCC Cancer Staging Atlas*. New York: Springer; 2006. Copyright © American Joint Committee on Cancer. Used with permission.



**Figure 3.** T3 is defined as tumor that invades the subserosa. Distal extension to duodenum does not affect T category. Modified from: Greene FL, Compton, CC, Fritz AG, et al, eds. *AJCC Cancer Staging Atlas*. New York: Springer; 2006. Copyright © American Joint Committee on Cancer. Used with permission.



**Figure 4.** T4a tumor penetrates serosa (visceral peritoneum) without invasion of adjacent structures, whereas T4b tumor invades adjacent structures, such as the pancreas (shown). Modified from: Greene FL, Compton, CC, Fritz AG, et al, eds. *AJCC Cancer Staging Atlas*. New York: Springer; 2006. Copyright © American Joint Committee on Cancer. Used with permission.

**Regional Lymph Nodes (N)** (also see Note K)

- NX Regional lymph nodes cannot be assessed
- N0 No regional lymph node metastasis<sup>#</sup>
- N1 Metastasis in 1 to 2 perigastric lymph nodes
- N2 Metastasis in 3 to 6 perigastric lymph nodes
- N3 Metastasis in more than 6 lymph nodes

<sup>#</sup>A designation of N0 should be used if all examined lymph nodes are negative, regardless of the total number removed and examined.<sup>1</sup>

**Distant Metastasis (M)**

- M0 No distant metastasis
- M1 Distant metastasis

**Stage Groupings**

Stage 0	Tis	N0	M0
Stage IA	T1	N0	M0
Stage 1B	T2	N0	M0
	T1	N1	M0
Stage IIA	T3	N0	M0
	T2	N1	M0
	T1	N2	M0
Stage IIB	T4a	N0	M0
	T3	N1	M0
	T2	N2	M0
Stage IIIA	T4a	N1	M0
	T3	N2	M0
	T2	N3	M0

Stage IIIB	T4b	N0 or N1	M0
	T4a	N2	M0
	T3	N3	M0
Stage IIIC	T4b	N2 or N3	M0
	T4a	N3	M0
Stage IV	Any T	Any N	M1

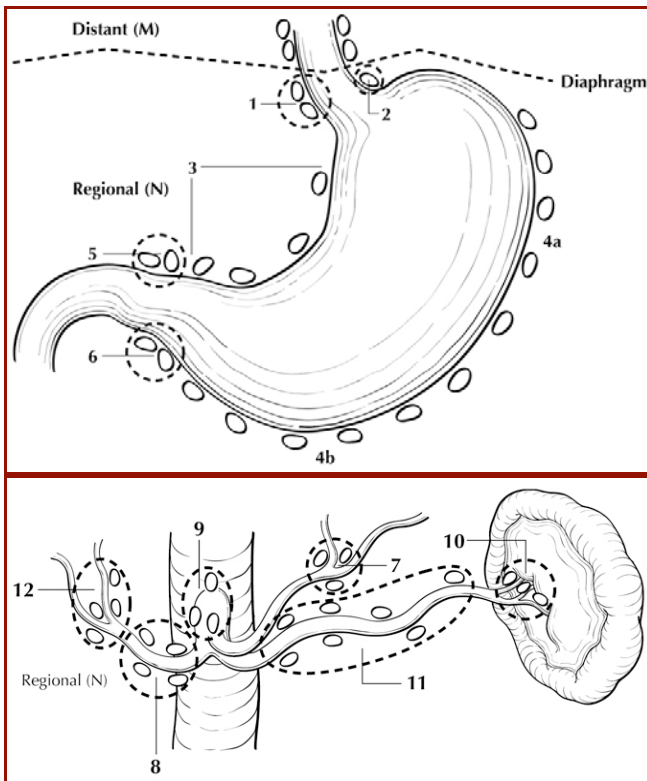
**Additional Descriptors**

Lymph-Vascular Invasion

Lymph-vascular invasion (LVI) indicates whether microscopic lymph-vascular invasion is identified in the pathology report. LVI includes lymphatic invasion, vascular invasion, or lymph-vascular invasion. By AJCC/UICC convention, LVI does not affect the T category indicating local extent of tumor unless specifically included in the definition of a T category.

**J. Regional Lymph Nodes**

The specific nodal areas of the stomach (Figure 5) are listed below.<sup>1</sup>



**Figure 5.** Regional lymph nodes of the stomach. From: Greene FL, Compton, CC, Fritz AG, et al, eds. *AJCC Cancer Staging Atlas*. New York: Springer; 2006. Copyright © American Joint Committee on Cancer. Used with permission.

Greater Curvature of Stomach: Greater curvature, greater omental, gastroduodenal, gastroepiploic, pyloric, and pancreaticoduodenal

Pancreatic and Splenic Area: Pancreaticolienal, peripancreatic, splenic  
Lesser Curvature of Stomach: Lesser curvature, lesser omental, left gastric, cardioesophageal, common hepatic, celiac, and hepatoduodenal

Involvement of other intra-abdominal lymph nodes, such as hepatoduodenal, retropancreatic, mesenteric, and para-aortic, is classified as distant metastasis.<sup>1</sup>

### K. Other Findings

One of the most important risk factors for development of gastric carcinoma is long-standing infection with *Helicobacter pylori*, which leads to chronic gastritis and mucosal atrophy with intestinal metaplasia; autoimmune gastritis, also a chronic inflammatory condition, is also associated with increased risk.<sup>18</sup> Occasionally, gastric carcinoma arises in a preexisting gastric polyp, most commonly large hyperplastic polyps in the setting of atrophic gastritis.

### L. Clinical History

Previous gastric surgery, such as Bilroth I or Bilroth II procedures, predisposes to the development of carcinoma in the remnant stomach; such tumors typically arise approximately 25 years after surgery for benign diseases.<sup>19</sup>

### References

1. Edge SB, Byrd DR, Carducci MA, Compton CC, eds. *AJCC Cancer Staging Manual*. 7th ed. New York, NY: Springer; 2009.
2. Chandrasoma P, Wickramasinghe K, Ma Y, DeMeester T. Adenocarcinomas of the distal esophagus and "gastric cardia" are predominantly esophageal carcinomas. *Am J Surg Pathol*. 2007;31(4):569-575.
3. Mattioli S, Ruffato A, Di Simone MP, et al. Immunopathological patterns of the stomach in adenocarcinoma of the esophagus, cardia, and gastric antrum: gastric profiles in Siewert type I and II tumors. *Ann Thorac Surg*. 2007;83(5):1814-1819.
4. Carneiro F, Chaves P. Pathologic risk factors of adenocarcinoma of the gastric cardia and gastroesophageal junction. *Surg Oncol Clin North Am*. 2006;15(4):697-714.
5. Hamilton SR, Aaltonen LA, eds. *World Health Organization Classification of Tumours: Pathology and Genetics of Tumours of the Digestive System*. Lyon, France: IARC Press; 2000.
6. Feith M, Stein HJ, Siewert JR. Adenocarcinoma of the esophagogastric junction: surgical therapy based on 1602 consecutive resected patients. *Surg Oncol Clin North Am*. 2006;15(4):751-764.
7. Glickman JN, Fox V, Antonioli DA, Wang HH, Odze RD. Morphology of the cardia and significance of carditis in pediatric patients. *Am J Surg Pathol*. 2002;26(8):1032-1039.
8. Cunningham SC, Kamangar F, Kim MP, et al. Survival after gastric adenocarcinoma resection: eighteen-year experience at a single institution. *J Gastrointest Surg*. 2005;9(5):718-725.
9. Talamonti MS, Kim SP, Yao KA, et al. Surgical outcomes of patients with gastric carcinoma: the importance of primary tumor location and microvessel invasion. *Surgery*. Oct 2003;134(4):720-727; discussion 727-729.

10. Lauren P. The two histological main types of gastric carcinoma. *Acta Pathol Microbiol Scand*. 1965;64:31-49.
11. Luebke T, Baldus SE, Grass G, et al. Histological grading in gastric cancer by Ming classification: correlation with histopathological subtypes, metastasis, and prognosis. *World J Surg*. 2005;29(11):1422-1427; discussion 1428.
12. Inoue K, Nakane Y, Michiura T, et al. Histopathological grading does not affect survival after R0 surgery for gastric cancer. *Eur J Surg Oncol*. 2002;28(6):633-636.
13. Ryan R, Gibbons D, Hyland JMP, et al. Pathological response following long-course neoadjuvant chemoradiotherapy for locally advanced rectal cancer. *Histopathology*. 2005;47:141-146.
14. Mansour JC, Tang L, Shah M, et al. Does graded histologic response after neoadjuvant chemotherapy predict survival for completely resected gastric cancer? *Ann Surg Oncol*. 2007;14(12):3412-3418.
15. Rohatgi PR, Mansfield PF, Crane CH, et al. Surgical pathology stage by American Joint Commission on Cancer criteria predicts patient survival after preoperative chemoradiation for localized gastric carcinoma. *Cancer*. 2006;107(7):1475-1482.
16. Fotia G, Marrelli D, De Stefano A, Pinto E, Roviello F. Factors influencing outcome in gastric cancer involving muscularis and subserosal layer. *Eur J Surg Oncol*. 2004;30(9):930-934.
17. An JY, Baik YH, Choi MG, Noh JH, Sohn TS, Kim S. Predictive factors for lymph node metastasis in early gastric cancer with submucosal invasion: analysis of a single institutional experience. *Ann Surg*. 2007;246(5):749-753.
18. Kelley JR, Duggan JM. Gastric cancer epidemiology and risk factors. *J Clin Epidemiol*. 2003;56(1):1-9.
19. An JY, Choi MG, Noh JH, Sohn TS, Kim S. The outcome of patients with remnant primary gastric cancer compared with those having upper one-third gastric cancer. *Am J Surg*. 2007;194(2):143-147.