

Protocol for the Examination of Specimens from Patients with Primary Non-Small Cell Carcinoma, Small Cell Carcinoma, or Carcinoid Tumor of the Lung

Based on AJCC/UICC TNM, 7th edition

Protocol web posting date: October 2009

Procedure

- Resection

Authors

Kelly J. Butnor, MD, FCAP*

Department of Pathology and Laboratory Medicine, Fletcher Allen Health Care/University of Vermont, Burlington, Vermont

Mary Beth Beasley, MD, FCAP

Department of Pathology, Mt. Sinai Medical Center, New York, New York

Philip T. Cagle, MD, FCAP

Department of Pathology, The Methodist Hospital, Houston, Texas

Steven M. Grunberg, MD

Department of Hematology/Oncology, Fletcher Allen Health Care/University of Vermont, Burlington, Vermont

Feng-Ming Kong, MD, PhD, MPH

Veteran Administration Health Center/University of Michigan, Ann Arbor, Michigan

Alberto Marchevsky, MD, FCAP

Department of Pathology, Cedars-Sinai Medical Center, Los Angeles, California

Nader T. Okby, MD, FCAP

Orange Pathology Associates, Orange Regional Medical Center, Middletown, New York

Victor L. Roggli, MD, FCAP

Department of Pathology, Duke University Medical Center, Durham, North Carolina

Saul Suster, MD, FCAP

Department of Pathology, The Medical College of Wisconsin, Milwaukee, Wisconsin

Henry D. Tazelaar, MD

Department of Laboratory Medicine and Pathology, Mayo Clinic Scottsdale, Scottsdale, Arizona

William D. Travis, MD, FCAP

Department of Pathology, Memorial Sloan-Kettering Cancer Center, New York, New York

For the Members of the Cancer Committee, College of American Pathologists

* denotes primary author. All other contributing authors are listed alphabetically.

Previous lead contributors: Anthony A. Gal, MD, Alberto Marchevsky, MD, William D. Travis, MD

© 2009 College of American Pathologists (CAP). All rights reserved.

The College does not permit reproduction of any substantial portion of these protocols without its written authorization. The College hereby authorizes use of these protocols by physicians and other health care providers in reporting on surgical specimens, in teaching, and in carrying out medical research for nonprofit purposes. This authorization does not extend to reproduction or other use of any substantial portion of these protocols for commercial purposes without the written consent of the College.

The CAP also authorizes physicians and other health care practitioners to make modified versions of the Protocols solely for their individual use in reporting on surgical specimens for individual patients, teaching, and carrying out medical research for non-profit purposes.

The CAP further authorizes the following uses by physicians and other health care practitioners, in reporting on surgical specimens for individual patients, in teaching, and in carrying out medical research for non-profit purposes: (1) **Dictation** from the original or modified protocols for the purposes of creating a text-based patient record on paper, or in a word processing document; (2) **Copying** from the original or modified protocols into a text-based patient record on paper, or in a word processing document; (3) The use of a **computerized system** for items (1) and (2), provided that the Protocol data is stored intact as a single text-based document, and is not stored as multiple discrete data fields.

Other than uses (1), (2), and (3) above, the CAP does not authorize any use of the Protocols in electronic medical records systems, pathology informatics systems, cancer registry computer systems, computerized databases, mappings between coding works, or any computerized system without a written license from CAP. Applications for such a license should be addressed to the SNOMED Terminology Solutions division of the CAP.

Any public dissemination of the original or modified Protocols is prohibited without a written license from the CAP.

The College of American Pathologists offers these protocols to assist pathologists in providing clinically useful and relevant information when reporting results of surgical specimen examinations of surgical specimens. The College regards the reporting elements in the "Surgical Pathology Cancer Case Summary (Checklist)" portion of the protocols as essential elements of the pathology report. However, the manner in which these elements are reported is at the discretion of each specific pathologist, taking into account clinician preferences, institutional policies, and individual practice.

The College developed these protocols as an educational tool to assist pathologists in the useful reporting of relevant information. It did not issue the protocols for use in litigation, reimbursement, or other contexts. Nevertheless, the College recognizes that the protocols might be used by hospitals, attorneys, payers, and others. Indeed, effective January 1, 2004, the Commission on Cancer of the American College of Surgeons mandated the use of the checklist elements of the protocols as part of its Cancer Program Standards for Approved Cancer Programs. Therefore, it becomes even more important for pathologists to familiarize themselves with these documents. At the same time, the College cautions that use of the protocols other than for their intended educational purpose may involve additional considerations that are beyond the scope of this document.

The inclusion of a product name or service in a CAP publication should not be construed as an endorsement of such product or service, nor is failure to include the name of a product of service to be construed as disapproval.

Surgical Pathology Cancer Case Summary (Checklist)

Protocol web posting date: October 2009

LUNG: Resection

Select a single response unless otherwise indicated.

Specimen

- Lung
 Lobe(s) of lung (specify): _____
 Bronchus (specify): _____
 Other (specify): _____
 Not specified

Procedure

- Major airway resection
 Wedge resection
 Segmentectomy
 Lobectomy
 Bilobectomy
 Pneumonectomy
 Other (specify): _____
 Not specified

Specimen Integrity

- Intact
 Disrupted
 Indeterminate

Specimen Laterality

- Right
 Left
 Not specified

Tumor Site (select all that apply)

- Upper lobe
 Middle lobe
 Lower lobe
 Other(s) (specify): _____
 Not specified

Tumor Size

- Greatest dimension: ____ cm
 *Additional dimensions: ____ x ____ cm
 Cannot be determined

* Data elements with asterisks are not required. However, these elements may be clinically important but are not yet validated or regularly used in patient management.

Tumor Focality (Note A)

- Unifocal
- Separate tumor nodules in same lobe
- Separate tumor nodules in different lobes (specify sites): _____
- Synchronous carcinomas (specify sites): _____
- Cannot be determined

Histologic Type (Note B)

- Carcinoma, type cannot be determined
- Non-small cell carcinoma, subtype cannot be determined
- Small cell carcinoma
- Combined small cell carcinoma (small cell carcinoma and non-small cell component) (specify type of non-small cell carcinoma component: _____)
- Squamous cell carcinoma
- Squamous cell carcinoma, papillary variant
- Squamous cell carcinoma, clear cell variant
- Squamous cell carcinoma, small cell variant
- Squamous cell carcinoma, basaloid variant
- Adenocarcinoma
- Adenocarcinoma, mixed subtype
- Acinar adenocarcinoma
- Papillary adenocarcinoma
- Bronchioloalveolar carcinoma
- Bronchioloalveolar carcinoma, nonmucinous
- Bronchioloalveolar carcinoma, mucinous
- Bronchioloalveolar carcinoma, mixed nonmucinous and mucinous
- Solid adenocarcinoma
- Fetal adenocarcinoma
- Mucinous (colloid) adenocarcinoma
- Mucinous cystadenocarcinoma
- Signet ring adenocarcinoma
- Clear cell adenocarcinoma
- Large cell carcinoma
- Large cell neuroendocrine carcinoma
- Combined large cell neuroendocrine carcinoma (specify type of other non-small cell carcinoma component: _____)
- Basaloid carcinoma
- Lymphoepithelioma-like carcinoma
- Clear cell carcinoma
- Large cell carcinoma with rhabdoid phenotype
- Adenosquamous carcinoma
- Sarcomatoid carcinoma
- Pleomorphic carcinoma
- Spindle cell carcinoma
- Giant cell carcinoma
- Carcinosarcoma
- Pulmonary blastoma
- Typical carcinoid tumor
- Atypical carcinoid tumor

* Data elements with asterisks are not required. However, these elements may be clinically important but are not yet validated or regularly used in patient management.

- Mucoepidermoid carcinoma
- Adenoid cystic carcinoma
- Epithelial-myoeplithelial carcinoma
- Other (specify): _____

Histologic Grade (Note C)

- Not applicable
- GX: Cannot be assessed
- G1: Well differentiated
- G2: Moderately differentiated
- G3: Poorly differentiated
- G4: Undifferentiated
- Other (specify): _____

Visceral Pleura Invasion (Note D)

- Not identified
- Present
- Indeterminate

Tumor Extension (select all that apply) (Note E)

- Not applicable
- Not identified
- Superficial spreading tumor with invasive component limited to bronchial wall
- Tumor involves main bronchus 2 cm or more distal to the carina
- Parietal pleura
- Chest wall
 - *Specify involved structure(s): _____
- Diaphragm
- Mediastinal pleura
- Phrenic nerve
- Parietal pericardium
- Tumor in the main bronchus less than 2 cm distal to the carina but does not involve the carina
- Mediastinum
 - *Specify involved structure(s): _____
- Heart
- Great vessels
- Trachea
- Esophagus
- Vertebral body
- Carina
- Other (specify): _____

* Data elements with asterisks are not required. However, these elements may be clinically important but are not yet validated or regularly used in patient management.

Margins (select all that apply) (Note F)Bronchial Margin

- Not applicable
 Cannot be assessed
 Uninvolved by invasive carcinoma
 Involved by invasive carcinoma
 Squamous cell carcinoma in situ (CIS) present at bronchial margin
 Squamous cell carcinoma in situ (CIS) not identified at bronchial margin

Vascular Margin

- Not applicable
 Cannot be assessed
 Uninvolved by invasive carcinoma
 Involved by invasive carcinoma

Parenchymal Margin

- Not applicable
 Cannot be assessed
 Uninvolved by invasive carcinoma
 Involved by invasive carcinoma

Parietal Pleural Margin

- Not applicable
 Cannot be assessed
 Uninvolved by invasive carcinoma
 Involved by invasive carcinoma

Chest Wall Margin

- Not applicable
 Cannot be assessed
 Uninvolved by invasive carcinoma
 Involved by invasive carcinoma

Other Attached Tissue Margin (specify): _____

- Not applicable
 Cannot be assessed
 Uninvolved by invasive carcinoma
 Involved by invasive carcinoma

If all margins uninvolved by invasive carcinoma:

Distance of invasive carcinoma from closest margin: ____ mm

Specify margin: _____

Treatment Effect (Note G)

- Not applicable
 Cannot be determined
 Greater than 10% residual viable tumor
 Less than 10% residual viable tumor

* Data elements with asterisks are not required. However, these elements may be clinically important but are not yet validated or regularly used in patient management.

***Tumor Associated Atelectasis or Obstructive Pneumonitis (Note H)**

- * ___ Extends to the hilar region but does not involve entire lung
- * ___ Involves entire lung

Lymph-Vascular Invasion (Note I)

- ___ Not identified
- ___ Present
- ___ Indeterminate

***Lymph Nodes (Note J)**

- * Extranodal extension
- * ___ Not identified
- * ___ Present

Pathologic Staging (pTNM) (Note J)

TNM Descriptors (required only if applicable) (select all that apply)

- ___ m (multiple primary tumors)
- ___ r (recurrent)
- ___ y (post-treatment)

Primary Tumor (pT)

- ___ pTX: Cannot be assessed, or tumor proven by presence of malignant cells in sputum or bronchial washings but not visualized by imaging or bronchoscopy
- ___ pT0: No evidence of primary tumor
- ___ pTis: Carcinoma in situ
- ___ pT1a: Tumor 2 cm or less in greatest dimension, surrounded by lung or visceral pleura, without bronchoscopic evidence of invasion more proximal than the lobar bronchus (ie, not in the main bronchus); or Superficial spreading tumor of any size with its invasive component limited to the bronchial wall, which may extend proximally to the main bronchus
- ___ pT1b: Tumor greater than 2 cm, but 3 cm or less in greatest dimension, surrounded by lung or visceral pleura, without bronchoscopic evidence of invasion more proximal than the lobar bronchus (ie, not in the main bronchus)
- ___ pT2a: Tumor greater than 3 cm, but 5 cm or less in greatest dimension surrounded by lung or visceral pleura, without bronchoscopic evidence of invasion more proximal than the lobar bronchus (ie, not in the main bronchus); or Tumor 5 cm or less in greatest dimension with any of the following features of extent: involves main bronchus, 2 cm or more distal to the carina; invades the visceral pleura; associated with atelectasis or obstructive pneumonitis that extends to the hilar region but does not involve the entire lung
- ___ pT2b: Tumor greater than 5 cm, but 7 cm or less in greatest dimension
- ___ pT3: Tumor greater than 7 cm in greatest dimension; or Tumor of any size that directly invades any of the following: chest wall (including superior sulcus tumors), diaphragm, phrenic nerve, mediastinal pleura, parietal pericardium; or Tumor of any size in the main bronchus less than 2 cm distal to the carina but without involvement of the carina; or

* Data elements with asterisks are not required. However, these elements may be clinically important but are not yet validated or regularly used in patient management.

- Tumor of any size associated with atelectasis or obstructive pneumonitis of the entire lung; or
 Tumors of any size with separate tumor nodule(s) in same lobe
 ___ pT4: Tumor of any size that invades any of the following: mediastinum, heart, great vessels, trachea, recurrent laryngeal nerve, esophagus, vertebral body, carina; or
 Tumor of any size with separate tumor nodule(s) in a different lobe of ipsilateral lung (**Note A**)

Regional Lymph Nodes (pN)

- ___ pNX: Cannot be assessed
 ___ pN0: No regional lymph node metastasis
 ___ pN1: Metastasis in ipsilateral peribronchial and/or ipsilateral hilar lymph nodes, and intrapulmonary nodes, including involvement by direct extension
 ___ pN2: Metastasis in ipsilateral mediastinal and/or subcarinal lymph node(s)
 ___ pN3: Metastasis in contralateral mediastinal, contralateral hilar, ipsilateral or contralateral scalene, or supraclavicular lymph node(s)

Specify: Number examined ____
 Number involved ____
 ___ Number cannot be determined (**Note J**)

If lymph node(s) involved, specify involved nodal station(s): _____

Distant Metastasis (pM)

- ___ Not applicable
 ___ pM1a: Separate tumor nodule(s) in contralateral lung; tumor with pleural nodules or malignant pleural (or pericardial) effusion (**Note A**)
 ___ pM1b: Distant metastases outside the lung/pleura
 *Specify site(s), if known: _____

***Additional Pathologic Findings (select all that apply)**

- * ___ None identified
 * ___ Atypical adenomatous hyperplasia
 * ___ Squamous dysplasia
 * ___ Metaplasia (specify type): _____
 * ___ Diffuse neuroendocrine hyperplasia
 * ___ Inflammation (specify type): _____
 * ___ Emphysema
 * ___ Other (specify): _____

***Ancillary Studies (select all that apply) (Note K)**

- * ___ Epidermal growth factor receptor (EGFR) analysis results
 (specify method): _____
 * ___ KRAS mutational analysis (specify results): _____
 * ___ Other (specify): _____

***Comment(s)**

* Data elements with asterisks are not required. However, these elements may be clinically important but are not yet validated or regularly used in patient management.

Explanatory Notes

A. Tumor Focality

There is evidence that patients with multiple tumor nodules of similar histology in the same lobe have markedly better survival than patients with tumors that meet the American Joint Committee on Cancer (AJCC) 7th edition TNM classification criteria for T4 (ie, invasion of mediastinal structures), and, in fact, their survival is similar to patients categorized as T3 in the AJCC 6th edition. For this reason, the presence of grossly recognizable multiple tumor nodules of similar histology in the same lobe are to be categorized as T3.¹ Survival among patients with multiple tumor nodule(s) of similar histology in ipsilateral separate lobes is similar to patients classified as T4, and therefore such tumors are to be categorized as T4.^{1,2} However, if separate tumors that are of similar histology in different segments, lobes, or lungs show an origin from carcinoma in situ, no carcinoma in lymphatics common to both tumors, and no extrapulmonary metastases at the time of diagnosis, they should be categorized as synchronous primary carcinomas and staged independently.³ Physically distinct and separate tumors of different histologic types are generally considered separate synchronous primaries and are staged separately.¹⁻³ In such cases, the highest T category is reported, followed in parentheses by multiplicity or number of tumors (eg, T2(m) or T2(5)).

B. Histologic Type

For consistency in reporting, the histologic classification published by the World Health Organization (WHO) for tumors of the lung, including carcinoids, is recommended.^{4,5} The histologic types are listed in this protocol in the order in which they appear in the WHO classification. This protocol does not preclude the use of other systems of classification of histologic types.⁶

The diagnosis of bronchioloalveolar carcinoma requires exclusion of stromal, vascular, and pleural invasion—a requirement that demands that the tumor be evaluated histologically in its entirety.⁴ It is therefore recommended that a definitive diagnosis of bronchioloalveolar adenocarcinoma not be made on specimens in which the tumor is incompletely represented.

C. Histopathologic Grade (G)

To standardize histologic grading, the following grading system is recommended.⁴

Grade X (GX): Cannot be assessed
Grade 1 (G1): Well differentiated
Grade 2 (G2): Moderately differentiated
Grade 3 (G3): Poorly differentiated
Grade 4 (G4): Undifferentiated

Undifferentiated (grade 4) is reserved for carcinomas that show minimal or no specific differentiation in routine histologic preparations. According to the definition of grading, a squamous cell carcinoma or an adenocarcinoma arising in the lung can be classified only as grade 1, grade 2, or grade 3, because by definition these tumors show squamous or glandular differentiation, respectively. If there are variations in the differentiation of a tumor, the least favorable variation is recorded as the grade, using grades 1 through 3. By definition, small cell and large cell carcinomas of the lung are assigned grade 4, because they are high-grade tumors with poor prognosis.

D. Visceral Pleural Invasion

The presence of visceral pleural invasion by tumors smaller than 3 cm changes the T category from pT1 to pT2 and increases the stage from IA to IB in patients with N0, M0 disease or stage IIA to IIB in patients with N1, M0 disease (M0 is defined as no distant metastasis).¹ Studies have shown that tumors smaller than 3 cm that penetrate beyond the elastic layer of the visceral pleura behave similarly to similar-size tumors that extend to the visceral pleural surface.^{7,8} Visceral pleural invasion should therefore be considered present not only in tumors that extend to the visceral pleural surface, but also in tumors that penetrate beyond the elastic layer of the visceral pleura (Figure).⁷⁻⁹ Elastic stains may aid in the assessment of visceral pleural invasion.^{7,10}

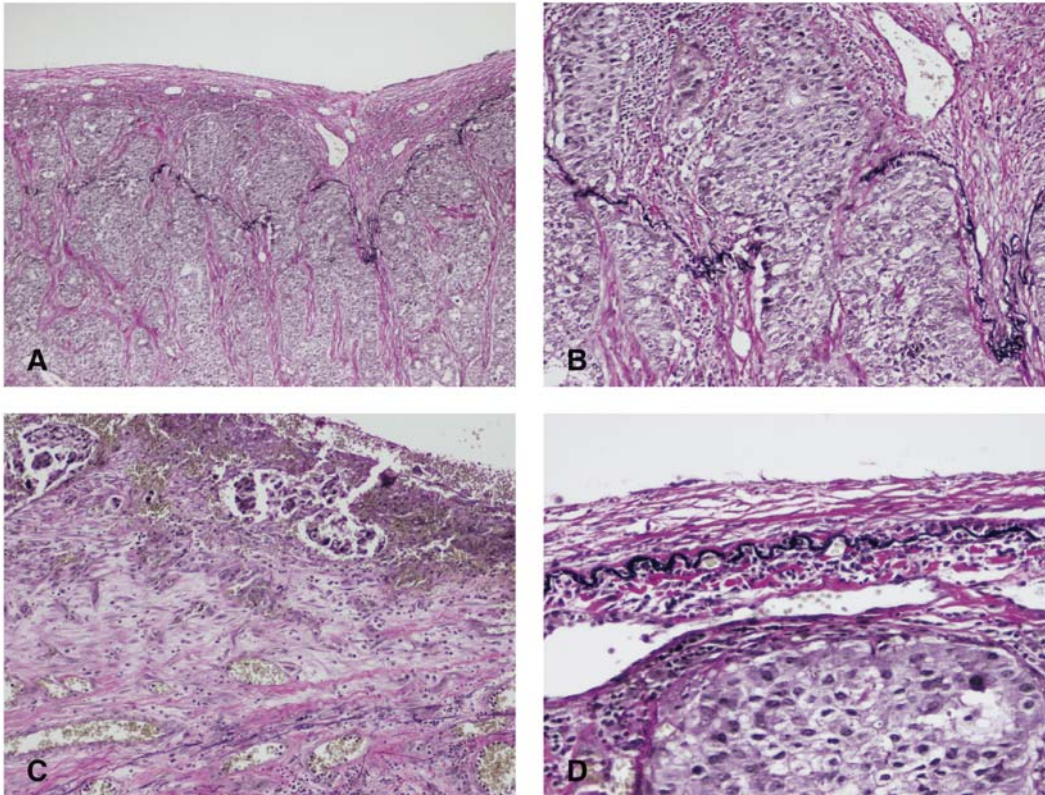


Figure. Types of visceral pleural invasion. Staining for elastin (eg, elastic-Van Gieson [EVG] stain) can aid in detection of visceral pleural invasion where it is indeterminate by hematoxylin-eosin (H&E) stain. A and B. Visceral pleural invasion is present when a tumor penetrates beyond the elastic layer of the visceral pleura (type PL1 pleural invasion) C. Tumor extension to the visceral pleural surface is also categorized as visceral pleural invasion (type PL2). Both types of visceral pleural invasion raise the T category of otherwise T1 tumors to T2. D. Visceral pleural invasion is categorized as absent in tumors that do not penetrate the visceral pleural elastic layer (type PL0). (Original magnifications x200 [A], x400 [B and C], x600 [D]).

Based on available data, a tumor with local invasion of another ipsilateral lobe without tumor on the visceral pleural surface should be classified as T2.¹⁰

Pleural tumor foci that are separate from direct pleural invasion should be categorized as M1a.²

E. Tumor Extension

According to the AJCC, direct invasion of the parietal pleura is categorized as T3, as is direct invasion of the chest wall.¹¹ Although not required, specifying the chest wall structures directly invaded by tumor (eg, intercostal muscle[s], rib[s], pectoralis muscle, latissimus muscle, serratus muscle) may facilitate patient management.

In addition to containing the heart and great vessels, the mediastinum includes the thymus and other structures between the lungs, direct invasion of any of which is considered T4.

Occasionally, lung cancer specimens consist of en bloc resections that incorporate other structures directly invaded by tumor that are not referred to in AJCC pathologic staging, but are discussed under the clinical staging section of the AJCC manual.¹¹ The T categories that correspond to direct invasion of these structures are summarized in the collaborative staging manual.¹² These should be reported under the “other” designation and include the following:

- Tumors with direct invasion of the phrenic nerve or brachial plexus (inferior branches or not otherwise specified) from the superior sulcus are categorized as T3.
- Superior sulcus tumors with encasement of subclavian vessels or unequivocal involvement of the superior branches of the brachial plexus are categorized as T4.
- Direct invasion of the visceral pericardium or cervical sympathetic, recurrent laryngeal, or vagus nerve(s) is considered T4.

F. Margins

Surgical margins represent sites that have either been cut or bluntly dissected by the surgeon to resect the specimen. The presence of tumor at a surgical margin is an important finding, because there is the potential for residual tumor remaining in the patient in the area surrounding a positive margin. Peripheral wedge resections contain a parenchymal margin, which is represented by the tissue at the staple line(s). Lobectomy and pneumonectomy specimens contain bronchial and vascular margins, and depending on the completeness of the interlobar fissures and other anatomic factors, may also contain parenchymal margins in the form of staple lines. En bloc resections in which extrapulmonary structures are part of the specimen contain additional margins (eg, parietal pleura, chest wall) that should be designated by the surgeon for appropriate handling. This includes cases in which the visceral pleura is adherent to the parietal pleura. Note that the visceral pleura is not a surgical margin.

G. Treatment Effect

For patients who have received neoadjuvant chemotherapy and/or radiation therapy before surgical resection, quantifying the extent of therapy-induced tumor regression provides prognostically relevant information.¹³ A “y” prefix is applied to the TNM classification in such cases (see Note J).

H. Tumor Associated Atelectasis or Obstructive Pneumonitis

Although the presence and extent of obstructive pneumonitis associated with tumor can sometimes be determined in pneumonectomy specimens, accurate assessment of tumor-associated atelectasis or obstructive pneumonitis typically requires integration of radiographic information.¹⁴

I. Vascular/Lymphatic Invasion

There is data showing that lymphovascular invasion by tumor may represent an unfavorable prognostic finding.¹⁵ Angiolymphatic invasion does not change the pT and pN classifications or the TNM stage grouping.

J. TNM and Stage Grouping

The TNM staging system of the American Joint Committee on Cancer (AJCC) and the International Union Against Cancer (UICC) is recommended for non-small cell lung cancer.^{11,16} Small cell lung cancer has been more commonly classified according to a separate staging system as either “limited” or “extensive” disease, but based on analysis of the International Association for the Study of Lung Cancer (IASLC) database, TNM staging is also recommended for small cell lung cancer.¹⁷⁻¹⁸ Carcinoid and atypical carcinoid tumors should also be classified according to the TNM Staging System.

By AJCC/UICC convention, the designation “T” refers to a primary tumor that has not been previously treated. The symbol “p” refers to the pathologic classification of the TNM, as opposed to the clinical classification, and is based on gross and microscopic examination. pT entails a resection of the primary tumor or biopsy adequate to evaluate the highest pT category, pN entails removal of nodes adequate to validate lymph node metastasis, and pM implies microscopic examination of distant lesions. Clinical classification (cTNM) is usually carried out by the referring physician before treatment during initial evaluation of the patient or when pathologic classification is not possible.

Pathologic staging is usually performed after surgical resection of the primary tumor. Pathologic staging depends on pathologic documentation of the anatomic extent of disease, whether or not the primary tumor has been completely removed. If a biopsied tumor is not resected for any reason (eg, when technically unfeasible) and if the highest T and N categories or the M1 category of the tumor can be confirmed microscopically, the criteria for pathologic classification and staging have been satisfied without total removal of the primary cancer.

T Category Considerations

The uncommon superficial spreading tumor of any size with its invasive component limited to the bronchial wall, which may extend proximal to the main bronchus, is classified as T1.¹¹

Most pleural effusions with lung cancer are due to tumor. However, in a few patients, multiple cytopathologic examinations of pleural fluid are negative for tumor, the fluid is nonbloody and is not an exudate. Where these elements and clinical judgment dictate that the effusion is not related to the tumor, the effusion should be excluded as a staging element, and the tumor should be classified as T1, T2, or T3.¹¹

Although pneumonectomy specimens allow assessment of tumor involvement of a main bronchus, determining the distance to the carina, which is necessary to accurately assign a T category for centrally located tumors, typically requires consultation with the surgeon, bronchoscopist, or radiologist.¹⁹

A number of other T category considerations are addressed above (see Notes **A**, **D**, **E**, and **G**).

N Category Considerations

Although extranodal extension of a positive mediastinal lymph node may represent an unfavorable prognostic finding, it does not change the pN classification or the TNM stage grouping.²⁰⁻²³ Extranodal extension refers to the extension of metastatic intranodal tumor beyond the lymph node capsule into the surrounding tissue. Direct extension of a primary tumor into a nearby lymph node does not qualify as extranodal extension.

In certain situations, in particular when lymph nodes are obtained by mediastinoscopy, it may not be possible to ascertain the actual number of nodes submitted for evaluation (unless it is specified by the surgeon), as the pieces of tissue submitted may represent multiple discrete nodes or multiple fragments of a single node. If nodal involvement is identified in this setting, the lymph node station(s) (see below) involved, if known, should be reported.

The anatomic classification of regional lymph nodes proposed by the International Association for the Study of Lung Cancer (IASLC) is shown below, which reconciles differences between the Naruke and Mountain/Dresler lymph node maps.^{11,24-25}

N2 Nodes

Station 1	Lower cervical, supraclavicular, and sternal notch nodes <u>Upper border</u> : lower margin of cricoid cartilage <u>Lower border</u> : clavicles bilaterally and, in the midline, the upper border of the manubrium, 1R designates right-sided nodes, 1L, left-sided nodes in this region
Station 2	Upper paratracheal nodes 2R: <u>Upper border</u> : apex of lung and pleural space <u>Lower border</u> : intersection of caudal margin of innominate vein with the trachea 2L: <u>Upper border</u> : apex of the lung and pleural space <u>Lower border</u> : superior border of the aortic arch
Station 3	Prevascular and retrotracheal nodes: 3A: prevascular; 3P: retrotracheal
Station 4	Lower paratracheal nodes: 4R: includes right paratracheal nodes, and pretracheal nodes extending to the left lateral border of trachea <u>Upper border</u> : lower border of origin of innominate artery <u>Lower border</u> : lower border of azygos vein 4L: includes nodes to the left of the left lateral border of the trachea, medial to the ligamentum arteriosum <u>Upper border</u> : upper margin of the aortic arch <u>Lower border</u> : upper rim of the left main pulmonary artery
Station 5	Subaortic nodes (aorto-pulmonary window): Subaortic nodes are lateral to the ligamentum arteriosum <u>Upper border</u> : the lower border of the aortic arch <u>Lower border</u> : upper rim of the left main pulmonary artery
Station 6	Para-aortic nodes (ascending aorta or phrenic): Nodes lying anterior and lateral to the ascending aorta and the aortic arch <u>Upper border</u> : a line tangential to the upper border of the aortic arch <u>Lower border</u> : the lower border of the aortic arch
Station 7	Subcarinal nodes <u>Upper border</u> : the carina of the trachea

Station 8	<p><u>Lower border</u>: the upper border of the lower lobe bronchus on the left; the lower border of the bronchus intermedius on the right</p> <p>Paraesophageal nodes (below carina): Nodes lying adjacent to the wall of the esophagus and to the right or left of the midline, excluding subcarinal nodes</p> <p><u>Upper border</u>: the upper border of the lower lobe bronchus on the left; the lower border of the bronchus intermedius on the right</p> <p><u>Lower border</u>: the diaphragm</p>
Station 9	<p>Pulmonary ligament nodes: Nodes lying within the pulmonary ligament</p> <p><u>Upper border</u>: the inferior pulmonary vein</p> <p><u>Lower border</u>: the diaphragm</p>
N1 Nodes	
Station 10	<p>Hilar nodes: Nodes immediately adjacent to the mainstem bronchus and hilar vessels including the proximal portions of the pulmonary veins and main pulmonary artery</p> <p><u>Upper border</u>: the lower rim of the azygos vein on the right; upper rim of the pulmonary artery on the left</p> <p><u>Lower border</u>: interlobar region bilaterally</p>
Station 11	<p>Interlobar nodes: Nodes lying between the origin of the lobar bronchi</p> <p>Optional notations for subcategories of Station 11:</p> <p>11s between the upper lobe bronchus and bronchus intermedius on the right</p> <p>11i between the middle and lower lobe bronchi on the right</p>
Station 12	Lobar nodes: Nodes adjacent to the lobar bronchi
Station 13	Segmental nodes: Nodes adjacent to the segmental bronchi
Station 14	Subsegmental nodes: Nodes around the subsegmental bronchi

Isolated tumor cells (ITCs) are single tumor cells or small clusters of cells not more than 0.2 mm in greatest dimension detected on routine sections or more commonly by immunohistochemistry or molecular methods. ITCs in lymph nodes or at distant sites should be classified as N0 or M0, respectively.¹¹

The following classification of ITCs may be used:

pN0(i-)	No regional lymph node metastasis histologically, negative morphological findings for ITC
pN0(i+)	No regional lymph node metastasis histologically, positive morphological findings for ITC
pN0(mol-)	No regional lymph node metastasis histologically, negative nonmorphological findings for ITC
pN0(mol+)	No regional lymph node metastasis histologically, positive nonmorphological findings for ITC

TNM Stage Groupings

Stage IA	T1a	N0	M0
	T1b	N0	M0
Stage IB	T2a	N0	M0
Stage IIA	T1a	N1	M0
	T1b	N1	M0
	T2a	N1	M0
	T2b	N0	M0
Stage IIB	T2b	N1	M0
	T3	N0	M0

Stage IIIA	T1a	N2	M0
	T1b	N2	M0
	T2a	N2	M0
	T2b	N2	M0
	T3	N1-2	M0
	T4	N0-1	M0
Stage IIIB	T1a	N3	M0
	T1b	N3	M0
	T2a	N3	M0
	T2b	N3	M0
	T3	N3	M0
	T4	N2-3	M0
Stage IV	Any T	Any N	M1a or M1b

TNM Descriptors

For identification of special cases of TNM or pTNM classifications, the “m” suffix and “y,” and “r” prefixes are used. Although they do not affect the stage grouping, they indicate cases needing separate analysis.

The “m” suffix indicates the presence of multiple primary tumors in a single site and is recorded in parentheses: pT(m)NM (see Note **A**).

The “y” prefix indicates those cases in which classification is performed during or following initial multimodality therapy (ie, neoadjuvant chemotherapy, radiation therapy, or both chemotherapy and radiation therapy). The cTNM or pTNM category is identified by a “y” prefix. The ycTNM or ypTNM categorizes the extent of tumor actually present at the time of that examination. The “y” categorization is not an estimate of tumor prior to multimodality therapy (ie, before initiation of neoadjuvant therapy) (see Note **F**).

The “r” prefix indicates a recurrent tumor when staged after a documented disease-free interval, and is identified by the “r” prefix: rTNM.

K. Ancillary Studies

The tyrosine kinase inhibitors (TKIs) erlotinib (Tarceva, Genentech, South San Francisco, California) and gefitinib (Iressa, AstraZeneca, Wilmington, Delaware) exhibit activity in some advanced non-small cell lung cancers. Individuals most likely to benefit from these agents include never smokers, individuals of Asian ethnicity, women, patients with adenocarcinoma, and those whose tumors show *EGFR* gene amplification and/or somatic mutations in the kinase domain of *EGFR*.²⁵⁻²⁸ Up to 20% of non-small cell lung cancers contain these *EGFR* mutations and around 80% to 85% of patients with such mutations respond to TKI treatment.²⁴⁻²⁵

Methods that have been purported to predict responsiveness to treatment with TKIs include polymerase chain reaction (PCR)-based *EGFR* mutational analysis and *EGFR* fluorescence in situ hybridization (FISH) amplification.²⁶⁻²⁹ The PCR method is designed to detect the most frequent *EGFR* mutations (exon 19 deletions and exon 21 L858R substitutions), which account for 85% to 90% of reported *EGFR* mutations. DNA is prepared from either frozen or formalin-fixed paraffin-embedded tissue, and exons 18 through 21 of the tyrosine kinase domain of the *EGFR* gene are amplified and bidirectionally sequenced to identify mutations. Mutations are confirmed by repeat sequencing of the tumor sample. *EGFR* gene amplification by FISH detects both gene

amplification (≥ 2.0 copies of *EGFR* as compared with a centromeric chromosome 7 control probe) and high polysomy (≥ 4 copies of *EGFR* per nucleus in $>40\%$ of nuclei).

Although immunohistochemical expression of EGFR is weakly correlated with increased *EGFR* copy number, neither EGFR or phosphorylated-EGFR immunorexpression correlate well with the presence of activating mutations.³⁰ Based on current data, EGFR immunohistochemistry appears not to have a significant role in the selection of patients likely to respond to TKIs.

In contrast to *EGFR* mutations, mutations in the K-ras gene (*KRAS*) are strongly correlated with a substantial smoking history, an overall poor prognosis, and a lack of response to EGFR inhibitors.³¹⁻³² Treating patients who have *KRAS*-mutated non-small cell lung cancer with EGFR TKIs may in fact be detrimental.³³ *KRAS* mutations, which are point mutations (most commonly affecting codon 12 and less often codon 13), are present in about one-quarter of lung adenocarcinomas. As with *EGFR* mutation analysis, testing for *KRAS* mutations is at present considered an investigational technique for guiding TKI treatment decisions.

References

1. Rami-Porta R, Ball D, Crowley J, et al. The IASLC lung cancer staging project: proposals for the revision of the T descriptors in the forthcoming (seventh) edition of the TNM classification for lung cancer. *J Thorac Oncol.* 2007;2(7):593-602.
2. Postmus P, Brambilla E, Chansky K, et al. The IASLC lung cancer staging project: proposals for revision of the M descriptors in the forthcoming (seventh) edition of the TNM classification of lung cancer. *J Thorac Oncol.* 2007;2(8):686-693.
3. Martini M, Melamed MR. Multiple primary lung cancers. *J Thorac Cardiovasc Surg.* 1975;70(4):606-612.
4. Travis WD, Brambilla E, Muller-Hermelink HK, Harris CC, eds. *World Health Organization Classification of Tumours. Pathology and Genetics. Tumours of the Lung, Pleura, Thymus and Heart.* Lyon, France: IARC Press; 2004.
5. Travis WD, Giroux DJ, Chansky K, et al. The IASLC lung cancer staging project: proposals for the inclusion of broncho-pulmonary carcinoid tumors in the forthcoming (seventh) edition of the TNM classification for lung cancer. *J Thorac Oncol.* 2008;3(11):1213-1223.
6. Mountain CF. The international system for staging lung cancer. *Semin Surg Oncol.* 2000;18(2):106-125.
7. Bunker ML, Raab SS, Landreneau RJ, et al. The diagnosis and significance of visceral pleura invasion in lung carcinoma: histologic predictors and the role of elastic stains. *Am J Clin Pathol.* 1999;112(6):777-783.
8. Shimizu K, Yoshida J, Nagai K, et al. Visceral pleural invasion classification in non-small cell lung cancer: a proposal on the basis of outcome assessment. *J Thorac Cardiovasc Surg.* 2004;127(6):1574-1578.
9. Hammar SP. Common neoplasms. In: Dail DH, Hammar SP, eds. *Pulmonary Pathology.* 2nd ed. New York, NY: Springer-Verlag; 1994:1123-1278.
10. Travis WD, Brambilla E, Rami-Porta R, et al. Visceral pleural invasion: pathologic criteria and use of elastic stains: proposal for the 7th edition of the TNM classification for lung cancer. *J Thorac Oncol.* 2008;3(12):1384-1390.
11. Lung. In: Edge SB, Byrd DR, Carducci MA, Compton CC, eds. *AJCC Cancer Staging Manual.* 7th ed. New York, NY: Springer; 2009.
12. Collaborative Staging Task Force of the American Joint Committee on Cancer. *Collaborative Staging Manual and Coding Instructions*, version 01.03.00. Jointly published by American Joint Committee on Cancer (Chicago, IL) and US

- Department of Health and Human Services (Bethesda, MD). 2004. NIH Publication Number 04-5496. Incorporates updates through September 8, 2006.
13. Junker K, Langer K, Klinke F, Bosse U, Thomas M. Grading of tumor regression in non-small cell lung cancer: morphology and prognosis. *Chest*. 2001;120(5):1584-1591.
 14. Marchevsky AM. Problems in pathologic staging of lung cancer. *Arch Pathol Lab Med*. 2006;130(3):292-302.
 15. Brechot JM, Chevret S, Charpentier MC, et al. Blood vessel and lymphatic vessel invasion in resected non-small cell lung carcinoma. *Cancer*. 1996;78(10):2111-2118.
 16. Sobin LH, Gospodarowicz M, Wittekind Ch, eds. *UICC TNM Classification of Malignant Tumours*. 7th ed. New York, NY: Wiley-Liss; 2009.
 17. Stahel R, Ginsberg R, Havemann K, et al. Staging and prognostic factors in small cell lung cancer: a consensus report. *Lung Cancer*. 1989;5(4-6):119-126.
 18. Shepherd FA, Crowley J, Van Houtte P, et al. The International Association for the Study of Lung Cancer staging project: proposals regarding the clinical staging of small cell lung cancer in the forthcoming (seventh) edition of the tumor, node, metastasis classification for lung cancer. *J Thorac Oncol*. 2007;2(12):1067-1077.
 19. Flieder DB. Commonly encountered difficulties in pathologic staging of lung cancer. *Arch Pathol Lab Med*. 2007;131(7):1016-1026.
 20. Riquet M, Manac'h D, Saab M, Le Pimpec-Barthes F, Dujon A, Debesse B. Factors determining survival in N2 lung cancer. *Eur J Cardiothorac Surg*. 1995;9(6):300-304.
 21. Mountain CF. The evolution of the surgical treatment of lung cancer. *Chest Surg Clin North Am*. 2000;10(1):83-104.
 22. Coughlin M, Deslauriers J, Beaulieu M, et al. Role of mediastinoscopy in pretreatment staging of patients with primary lung cancer. *Ann Thorac Surg*. 1985;40(6):556-560.
 23. Rusch VW, Crowley J, Giroux DJ, et al. The IASLC lung cancer staging project: proposals for the revision for the N descriptors in the forthcoming seventh edition of the TNM classification for lung cancer. *J Thorac Oncol*. 2007;2(7):603-612.
 24. Mountain CF, Dresler CM. Regional lymph node classification for lung cancer staging. *Chest*. 1997;111(6):1718-1723.
 25. The Japan Lung Cancer Society. *Classification of Lung Cancer*. 1st English ed. Tokyo, Japan: Kanehara & Co; 2000.
 26. Paez JG, Janne PA, Lee JC, et al. EGFR mutations in lung cancer: correlation with clinical response to gefitinib therapy. *Science*. 2004;304(5676):1497-1500.
 27. Daniele L, Macri L, Schena M, et al. Predicting gefitinib responsiveness in lung cancer by fluorescence in situ hybridization/chromogenic in situ hybridization analysis of EGFR and HER2 in biopsy and cytology specimens. *Mol Cancer Ther*. 2007;6(4):1223-1229.
 28. Cappuzzo F, Hirsch FR, Rossi E, et al. Epidermal growth factor receptor gene and protein and gefitinib sensitivity in non-small-cell lung cancer. *J Natl Cancer Inst*. 2005;97(9):643-55.
 29. Hirsch FR, Varella-Garcia M, Bunn PA Jr, et al. Epidermal growth factor receptor in non-small-cell lung carcinomas: correlation between gene copy number and protein expression and impact on prognosis. *J Clin Oncol*. 2003;21(20):3798-807.
 30. Motoi N, Szoke J, Riely GJ, et al. Lung adenocarcinoma: modification of the 2004 WHO mixed subtype to include the major histologic subtype suggests correlations between papillary and micropapillary adenocarcinoma subtypes, EGFR mutations and gene expression analysis. *Am J Surg Pathol*. 2008;32(6):810-27.

31. Pao W, Miller VA, Politi KA, et al. Acquired resistance of lung adenocarcinomas to gefitinib or erlotinib is associated with a second mutation in the EGFR kinase domain. *PLoS Med.* 2005;2(3):e73. Epub 2005 Feb 22.
32. Ahrendt SA, Decker PA, Alawi EA, et al. Cigarette smoking is strongly associated with mutation of the K-ras gene in patients with primary adenocarcinoma of the lung. *Cancer.* 2001;92(6):1525-30.
33. Tsao M, Zhy C, Sakurada A, et al. An analysis of the prognostic and predictive importance of K-ras mutation status in the National Cancer Institute of Canada Clinical Trials Group BR.21 study of erlotinib versus placebo in the treatment of non-small cell lung cancer. *J Clin Oncol.* 2006;24(18s)(suppl). Abstract 7005.